

ISSN 2816-9506 (PRINT)

ISSN 2816-9514 (ONLINE)

Volume 2, Issue 2

# CANADIAN EYE CARE TODAY

---

## **Management of Recurrent Corneal Erosions: A Stepwise Approach**

Yelin Yang, MD

## **Trocar-based Surgical Technique for Drainage of Suprachoroidal Hemorrhages**

David RP Almeida, MD, MBA, PhD  
Eric K. Chin, MD

## **Anti-VEGF Therapy in Pregnancy and Breastfeeding**

Amy Basilius, MD  
Rajeev H. Muni, MD  
Verena R. Juncal, MD

## **Medical Management of Glaucoma for the Pregnant and Breastfeeding Patient**

Gurkaran S. Sarohia, MD  
Mathew M. Palakkamanil, MD, MPH, FRCSC

## **The Evolving Role of Women in Ophthalmology: Can They Truly Lean In?**

Marie-Claude Robert, MD

# EDITORIAL BOARD



**CLARA C. CHAN, MD, FRCSC, FACS**  
Associate Professor, University of Toronto  
Department of Ophthalmology and Vision Sciences  
Medical Director, Eye Bank of Canada (Ontario division)



**HADY SAHEB, MD, MPH**  
Glaucoma and Complex Anterior Segment Surgeon  
Director of Glaucoma Fellowship McGill University



**R. RISHI GUPTA, MD, FRCSC, FASRS**  
Associate Professor of Ophthalmology  
Department of Ophthalmology and Visual Sciences  
Dalhousie University, Halifax, Nova Scotia

# TABLE OF CONTENTS

<b>Management of Recurrent Corneal Erosions: A Stepwise Approach</b> Yelin Yang, MD	<b>04</b>
<b>Trocar-based Surgical Technique for Drainage of Suprachoroidal Hemorrhages</b> David RP Almeida, MD, MBA, PhD Eric K. Chin, MD	<b>10</b>
<b>Anti-VEGF Therapy in Pregnancy and Breastfeeding</b> Amy Basiliou, MD Rajeev H. Muni, MD Verena R. Juncal, MD	<b>15</b>
<b>Medical Management of Glaucoma for the Pregnant and Breastfeeding Patient</b> Gurkaran S. Sarohia, MD Mathew M. Palakkamanil, MD, MPH, FRCSC	<b>21</b>
<b>The Evolving Role of Women in Ophthalmology: Can They Truly Lean In?</b> Marie-Claude Robert, MD	<b>27</b>

*Canadian Eye Care Today* is published 3 times per year in English.

#### **Open Access**

Canadian Eye Care Today is an open access journal, which means all its content is freely available without charge. Users are permitted to copy and redistribute the material in any medium or format for any noncommercial purpose, provided they cite the source.

#### **License**

© Canadian Eye Care Today. Licensed under CC BY-NC-ND 4.0.

To learn more please visit [canadianeyecaretoday.com](http://canadianeyecaretoday.com)

The content in *Canadian Eye Care Today* qualifies for Section 2 (self-learning) credits towards the maintenance of certification. For information on how this activity fits in the Royal College Maintenance of Certification (MOC) Program, please visit the Royal College's website ([royalcollege.ca/moc](http://royalcollege.ca/moc)). For more personalized support, please contact the Royal College Services Centre (1-800-461-9598) or your local CPD Educator.

If you would like to contribute to a future issue of *Canadian Eye Care Today* please email us at [info@catalytichealth.com](mailto:info@catalytichealth.com)

# ABOUT THE AUTHOR



**YELIN YANG, MD:** Yelin Yang received her Bachelor of Health Sciences from McMaster University followed by Doctor of Medicine from University of Ottawa. She completed her ophthalmology residency at University of Toronto, and fellowship in Cornea and External Diseases at University of Montreal. She is currently practicing at Toronto East General Hospital.

## Management of Recurrent Corneal Erosions: A Stepwise Approach

Yelin Yang, MD

**Affiliations:**

Michael Garron (Toronto East General) Hospital

**Correspondence:**

Yelin Yang  
Email: yelinyang@gmail.com

**Financial Disclosures:**

None

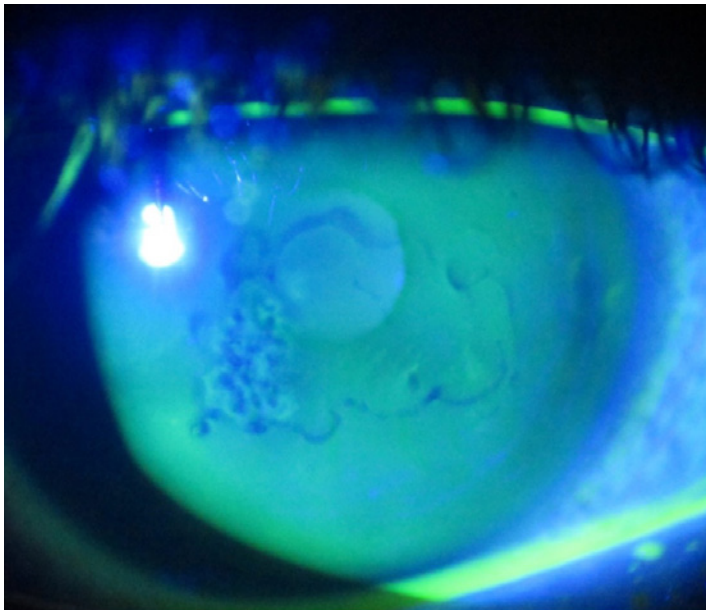
Recurrent corneal erosions syndrome (RCES) is a common disorder characterized by recurring episodes of corneal epithelial breakdown.<sup>1</sup> Symptoms include pain, tearing or redness typically worse upon awakening or overnight during rapid eye movements (REM) sleep. Severe episodes can last for days, leading to epithelial defects and corneal scarring. Recurrences can be frequent and debilitating for patients. The aim of this review is to summarize the current medical and surgical methods available to treat RCES.

**Etiology**

The two most common causes of RCES are trauma and epithelial basement membrane dystrophy (EBMD) (**Figure 1**).<sup>2</sup> Within the trauma group,

finger nail trauma is the most common. Other frequent modalities of trauma include those from paper, tree branch and mascara brush injuries. Other predisposing factors include corneal dystrophies such as lattice and Reis-Bücklers dystrophy, dry eye, meibomian gland disease, rosacea, and diabetes.<sup>2</sup>

The mechanism likely involves abnormal hemidesmosomes and anchoring filaments, leading to poor adhesion of corneal epithelium to the underlying stroma.<sup>1</sup> Epithelial trauma results in defective adhesion complex formation, while EBMD is characterized by an abnormal and multilaminar basement membrane that leads to poor adhesion. Patients with RCES, especially those with meibomian gland disease and rosacea, have also been found



**Figure 1.** Slit lamp photograph demonstrating negative staining in epithelial basement membrane dystrophy; courtesy of Dr. Clara C. Chan.

to have higher levels of matrix metalloproteinases (MMPs) in tear fluid, which promotes cleavage of collagen and adhesion proteins.<sup>3</sup> In addition, dry eye may contribute to RCES by increasing adhesion between the lids and corneal epithelium. The shearing forces from rapid opening of the eyelid can lead to corneal erosions.

**Medical Treatment**

There is a wide range of treatment options available; treatment can be approached in a stepwise fashion with the objective of improving epithelial and basement membrane adhesions. Most patients can be managed initially with medical therapy (**Figure 2**).

First-line treatment includes lubrication and the application of nightly ointment. The choice of additional treatment depends on patient preferences while targeting the underlying ocular comorbidities such as dry eyes and meibomian gland dysfunction (MGD).

*Acute period*

Typically, patients presenting with an acute erosion are initially treated with antibiotic ointment/drops and artificial tears. Depending on the severity of the episode, patching, bandage contact lenses (BCLs) or cycloplegic eye drops can be added for comfort. A BCL acts as a mechanical barrier from the debridement action of the eyelid and provides a scaffold for healing. A prophylactic antibiotic is subsequently added to prevent microbial keratitis.

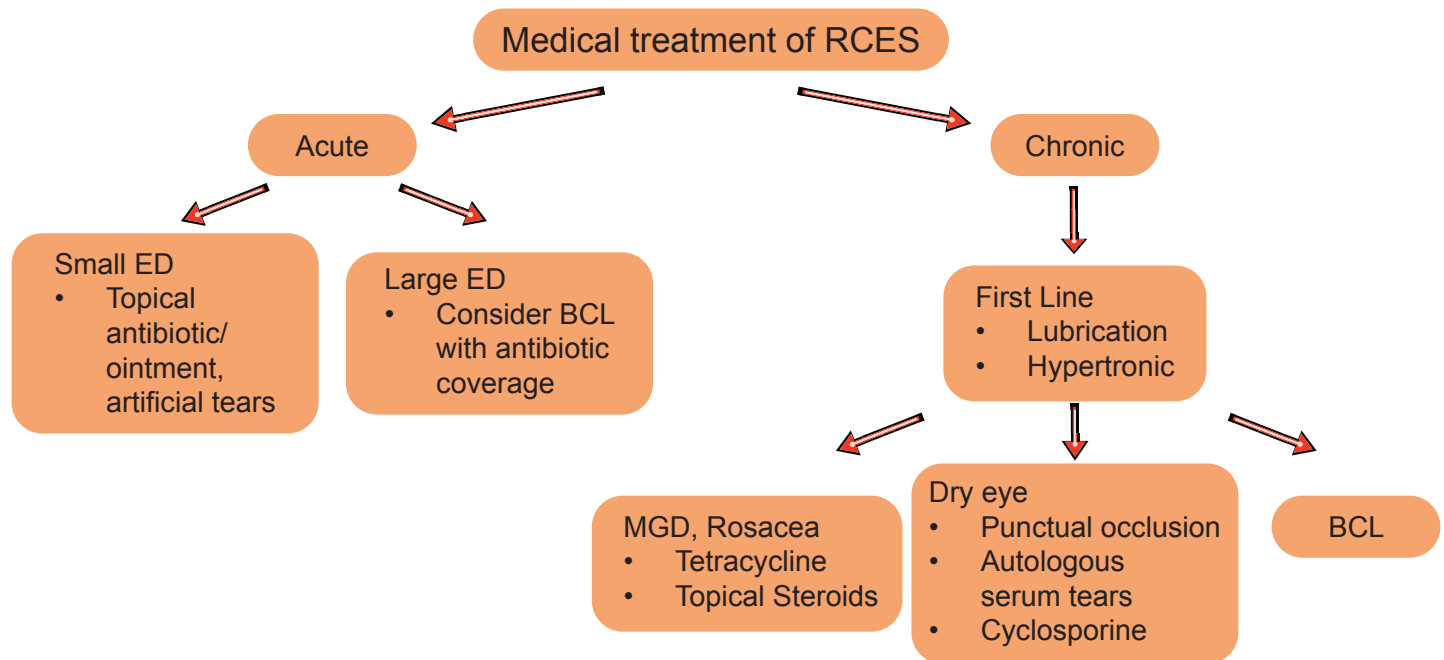
*Chronic period*

Lubrication and hypertonic saline

Lubrication with preservative-free artificial tears and lubricating ointment at nighttime is first-line treatment. Ointment at nighttime helps to prevent the eyelid from adhering to the corneal epithelium. A hypertonic saline ointment can also be used, which reduces epithelial edema and promotes epithelial adherence.<sup>1</sup> This protocol is typically continued for 6-12 months to allow the adhesion complexes to rebuild.

MMP inhibitors

Oral tetracycline and topical steroids inhibit MMP, which is thought to be involved in the cleavage of



**Figure 2.** Medical treatment options for recurrent corneal erosion syndrome (RCES); courtesy of Yelin Yang, MD RCES= recurrent corneal erosions syndrome; ED= epithelial debridement; BCL= bandage contact lenses; MGD= meibomian gland dysfunction

adhesion proteins. A combination of doxycycline 50 mg twice daily for 2 months and topical steroid used three times daily for 2-4 weeks was found to be effective in eyes with recalcitrant recurrent erosions.<sup>4,5</sup> Doxycycline may be particularly beneficial in patients with MGD and ocular rosacea as it inhibits lipase production. Patients with these conditions tend to accumulate higher levels than normal of lipases from colonizing bacteria; this creates toxic free fatty acids that negatively impact epithelial membrane healing.<sup>5</sup> Associated blepharitis should also be treated with lid hygiene and warm compresses.

#### Punctal occlusion

Punctal occlusion may be useful in patients with chronic dry eye where lubrication alone is insufficient. This increases the tear lake and may promote more rapid healing.<sup>1</sup>

#### Serum tears

Autologous serum tears contain proteins such as fibronectin, epidermal growth factor and Vitamin A, which promote epithelial migration and anchorage.<sup>6</sup> They have been used in patients failing conventional therapy such as lubrication, hypertonic solution, anterior stromal puncture (ASP), and BCL.<sup>6,7</sup> They are typically administered for 3-6 months, at a dose of 4-6 times daily with a tapering course. Clinical studies have demonstrated favourable results, with a reduction from 2.2 recurrences per month pre-treatment to 0.028 recurrences per month post-treatment.<sup>7</sup> Long-term clinical studies have reported a recurrence rate of 15% over a follow-up period of 12 months.<sup>6</sup>

#### Topical cyclosporine

Topical cyclosporine can be helpful in patients with chronic dry eye by improving tear film quality and goblet cell numbers, thereby reducing the mechanical friction that can lead to erosions. It has been used in patients with refractory RCES and persistent epithelial defects in a small case series.<sup>8</sup>

#### BCL

In addition to treating large erosions in the acute period of RCES, a BCL maybe be applied for an extended period of time for up to 3 months. The lens should have a flat base curve and high oxygen permeability.<sup>1</sup> Clinical study results are varied, with some studies reporting favourable results. Conversely, a randomized clinical trial demonstrated no results difference between topical lubricants and extended wear BCLs.<sup>9,10</sup> BCLs are more likely to be

helpful in patients with evidence of active erosions with fluorescein staining, without significant MGD or ocular rosacea. Close follow-up is important due to the risk of microbial keratitis, and coverage with topical antibiotic is indicated. The percentage of basal cell membrane occupied by hemidesmosomes has been shown to increase for 6 weeks before stabilizing. As a result, it has been suggested that a minimum of 6 weeks of BCL wear is recommended to allow sufficient epithelial basement membrane remodelling.<sup>9</sup>

#### **Surgical Treatment**

Various surgical options are available for patients who fail conservative therapy (**Table 1**). It has been estimated that approximately 50% of patients with RCES may require surgical intervention.<sup>2</sup>

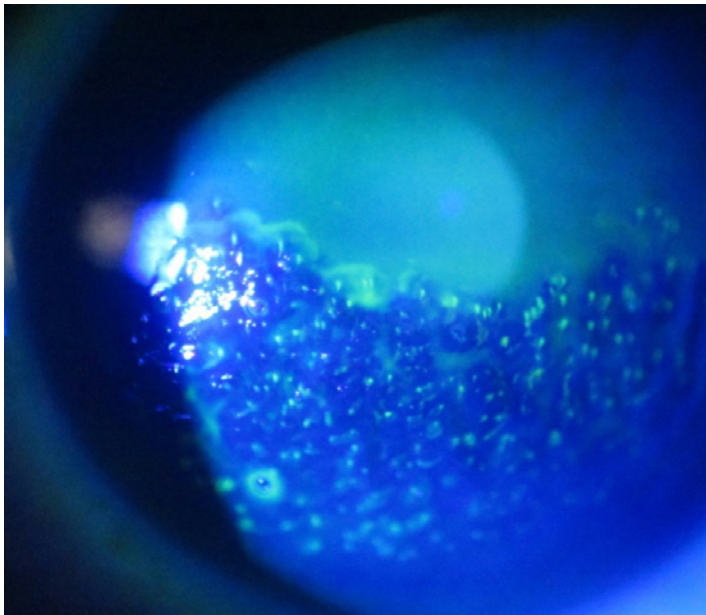
ASP is a procedure that can be performed in office. A bent 25- or 27-gauge needle is used to make superficial punctures through the Bowman's layer approximately 0.5 mm apart (**Figure 3**). The superficial punctures are thought to promote formation of firmer adhesions between the epithelium and basement membranes.<sup>1</sup> ASP tends to be used for peripheral lesions not involving the central visual axis as it can induce scarring if performed overly aggressively. Previous clinical studies have reported recurrence rates between 17% and 40% following ASP alone.<sup>2,11</sup> ASP can be combined with epithelial debridement to reduce recurrence. When combined, a recurrence rate of approximately 29% has been reported at mean follow up of 1.4 years.<sup>12</sup>

In epithelial debridement (ED), loose epithelium is removed to promote healing from the healthy edge.<sup>13,14</sup> It is typically removed with a rounded blade; subsequently, a BCL is put in place to promote re-epithelialization with topical antibiotic coverage. This is helpful for cases with loose epithelium that is freely mobile. However, ED as monotherapy has a high recurrence rate as it does not address the abnormal basement membrane, and typically it is insufficient for dystrophic cases presenting with RCES.

To reduce recurrence, ED can be combined with diamond burr polishing. Diamond burr is applied to the debrided area for approximately 10 seconds to gently polish the Bowman's membrane. This creates a slightly rough surface to which the new epithelium can adhere and may lead to more rapid re-epithelialization.<sup>15</sup> In addition, the polishing may stimulate reactive fibrosis, which allows stronger

Surgical treatment	Advantages	Disadvantages	Recurrence rate
ASP (can be combined with ED)	In-office, low cost	Leaves scar, avoid lesions in visual axis	17%-40% <sup>2,11,12</sup>
Epithelial debridement	Low cost	Not sufficient for dystrophy	18%-56% <sup>2,15</sup>
Epithelial debridement + Diamond burr polishing	Lower recurrence	Higher risk of haze	4%-25% <sup>2,16,17</sup>
Epithelial debridement + Alcohol delamination	Low cost, lower recurrence	Risk of toxicity, newer technique	8%-26% <sup>18,19</sup>
PTK	Lower recurrence	Cost, laser required Higher risk of haze Refractive shift	10%-36% <sup>21-23</sup>

**Table 1.** Surgical treatment options for recurrent corneal erosion syndrome (RCES); courtesy of Yelin Yang, MD  
 ASP= anterior stromal puncture ; PTK= phototherapeutic keratectomy



**Figure 3.** Slit lamp photograph demonstrating superficial punctures in anterior stromal puncture; courtesy of Dr. Clara C. Chan.

adhesion of the epithelium to the stroma. Clinical studies have reported recurrence rates following diamond burr polishing at between 4% and 25%.<sup>2,15,16</sup> However, vigorous polishing is not recommended as it can damage the Bowman's layer and cause reactive scarring.<sup>1</sup> Risk of corneal haze has been reported in up to 40% of cases following diamond burr polishing.<sup>15</sup> However, the majority of cases are mild and improve over time, with only 4% demonstrating persistent haze at 6 months.<sup>15</sup> Caution should be exercised when performing this procedure and only a large diameter brush should be used to avoid irregular astigmatism or excessive stromal thinning.

Alcohol delamination is a technique that is thought to create a smooth epithelial surface for healing and facilitate epithelial attachment.<sup>17</sup> Twenty percent alcohol is applied to the epithelium for approximately 40 seconds, followed by copious irrigation and removal of the epithelium.<sup>17</sup> Small clinical studies suggest that the recurrence rate with alcohol

delamination is 8%-26%.<sup>17,18</sup> However, there is a risk of toxicity with the use of alcohol, along with reduced viability of the epithelial cells, and greater inflammatory markers have been demonstrated in *in vitro* studies.<sup>19</sup> Additional long-term clinical studies are needed to validate this technique.

In phototherapeutic keratectomy (PTK), excimer laser removes the Bowman's layer and outer 5-10  $\mu\text{m}$  of stroma to create a smooth surface. This allows the epithelium to regrow with a stronger attachment, and new basement membranes/ hemidesmosomes have been shown to form within 2 weeks.<sup>13</sup> The recurrence rate with PTK is comparable to that of diamond burr polishing, reported at between 11% and 36%.<sup>20-22</sup> Deeper ablations can be associated with corneal haze and refractive shift.<sup>13</sup> Lower energy, a larger treatment zone and slight hyperopic treatment can be used to minimize the refractive shift.

#### Comparison between surgical treatments

Decision-making regarding the type of intervention to use is multifactorial, involving considerations of risks, costs, equipment availability, surgeon preferences, and the nature of the pathology. For peripheral lesions not involving the visual axis, ASP can be attempted. For erosions involving the central cornea, ED combined with diamond burr, alcohol delamination, or PTK can be performed with low rates of recurrence. In comparison, PTK involves the use of a laser and may be less accessible due to its cost.

## Conclusion

RCES is a challenging condition that can have significant impact on patient quality of life. There are multiple treatment options available. Topical lubrication and nightly ointment are first-line treatments, while additional medical treatments such as MMP inhibitors, BCLs and cyclosporine can be used for patients with underlying ocular comorbidities or those wishing to delay surgical intervention. The optimal approach to surgical treatment is to tailor it to the patient, bearing in mind the nature of the pathology, risks of the procedure, costs and facilities available. With appropriate therapy, most patients can achieve long-term resolution.

## References

1. Miller DD, Hasan SA, Simmons NL, Stewart MW. Recurrent corneal erosion: a comprehensive review. *Clinical Ophthalmology (Auckland, NZ)*. 2019;13:325.
2. Reidy JJ, Paulus MP, Gona S. Recurrent erosions of the cornea: epidemiology and treatment. *Cornea*. 2000 Nov 1;19(6):767-71.
3. Ramamurthi S, Rahman MQ, Dutton GN, Ramaesh K. Pathogenesis, clinical features and management of recurrent corneal erosions. *Eye*. 2006 Jun;20(6):635-44.
4. Dursun D, Kim MC, Solomon A, Pflugfelder SC. Treatment of recalcitrant recurrent corneal erosions with inhibitors of matrix metalloproteinase-9, doxycycline and corticosteroids. *American journal of Ophthalmology*. 2001 Jul 1;132(1):8-13.
5. Wang L, Tsang H, Coroneo M. Treatment of recurrent corneal erosion syndrome using the combination of oral doxycycline and topical corticosteroid. *Clinical & Experimental Ophthalmology*. 2008 Jan;36(1):8-12.
6. Ziakas NG, Boboridis KG, Terzidou C, Naoumidi TL, Mikropoulos D, Georgiadiou EN, Georgiadi NS. Long-term follow up of autologous serum treatment for recurrent corneal erosions. *Clinical & Experimental Ophthalmology*. 2010 Oct;38(7):683-7.
7. del Castillo JM, de la Casa JM, Sardiña RC, Fernández RM, Feijoo JG, Gómez AC, Rodero MM, Sánchez JG. Treatment of recurrent corneal erosions using autologous serum. *Cornea*. 2002 Nov 1;21(8):781-3.
8. Napoli PE, Braghiroli M, Iovino C, Demarinis G, Fossarello M. A study of refractory cases of persistent epithelial defects associated with dry eye syndrome and recurrent corneal erosions successfully treated with cyclosporine A 0.05% eye drops. *Drug Design, Development and Therapy*. 2019 Jun 19:2001-8.
9. Fraunfelder FW, Cabezas M. Treatment of recurrent corneal erosion by extended-wear bandage contact lens. *Cornea*. 2011 Feb 1;30(2):164-6.
10. Ahad MA, Anandan M, Tah V, Dhingra S, Leyland M. Randomized controlled study of ocular lubrication versus bandage contact lens in the primary treatment of recurrent corneal erosion syndrome. *Cornea*. 2013 Oct 1;32(10):1311-4.
11. Zauberman NA, Artornsombudh P, Elbaz U, Goldich Y, Rootman DS, Chan CC. Anterior stromal puncture for the treatment of recurrent corneal erosion syndrome: patient clinical features and outcomes. *American Journal of Ophthalmology*. 2014 Feb 1;157(2):273-9.
12. Yang Y, Mimouni M, Trinh T, Sorkin N, Cohen E, Santaella G, Rootman DS, Chan CC, Slomovic AR. Phototherapeutic keratectomy versus epithelial debridement combined with anterior stromal puncture or diamond burr for recurrent corneal erosions. *Canadian Journal of Ophthalmology*. 2022 Feb 22.
13. Ramamurthi S, Rahman MQ, Dutton GN, Ramaesh K. Pathogenesis, clinical features and management of recurrent corneal erosions. *Eye*. 2006 Jun;20(6):635-44.
14. Bae SS, Chan CC. Superficial keratectomy: indications and outcomes. *Canadian Journal of Ophthalmology*. 2018 Dec 1;53(6):553-9.
15. Wong VW, Chi SC, Lam DS. Diamond burr polishing for recurrent corneal erosions: results from a prospective randomized controlled trial. *Cornea*. 2009 Feb 1;28(2):152-6.
16. Soong HK, Farjo Q, Meyer RF, Sugar A. Diamond burr superficial keratectomy for recurrent corneal erosions. *British Journal of Ophthalmology*. 2002 Mar 1;86(3):296-8.
17. Dua HS, Lagnado R, Raj D, Singh R, Mantry S, Gray T, Lowe J. Alcohol delamination of the corneal epithelium: an alternative in the management of recurrent corneal erosions. *Ophthalmology*. 2006 Mar 1;113(3):404-11.
18. Mhéalóid ÁN, Lukasik T, Power W, Murphy CC. Alcohol delamination of the corneal epithelium for recurrent corneal erosion syndrome. *International Journal of Ophthalmology*. 2018;11(7):1129.
19. Oh JY, Yu JM, Ko JH. Analysis of ethanol effects on corneal epithelium. *Investigative Ophthalmology & Visual Science*. 2013 Jun 1;54(6):3852-6.
20. Maini R, Loughnan MS. Phototherapeutic keratectomy re-treatment for recurrent corneal erosion syndrome. *British Journal of Ophthalmology*. 2002 Mar 1;86(3):270-2.
21. Cavanaugh TB, Lind DM, Cutarelli PE, Mack RJ, Durrie DS, Hassanein KM, Graham CE. Phototherapeutic keratectomy for recurrent erosion syndrome in anterior basement membrane dystrophy. *Ophthalmology*. 1999 May 1;106(5):971-6.
22. Barylak J, Pan YI, Hodge WG. Long-term efficacy of phototherapeutic keratectomy on recurrent corneal erosion syndrome. *Cornea*. 2006 Dec 1;25(10):1150-2.



In your patients with moderate-to-severe keratoconjunctivitis sicca (dry eye),

## Discover increased tear production with CEQUA™

PrCEQUA™ (cyclosporine ophthalmic solution, 0.09% w/v) is indicated to increase tear production in patients with moderate-to-severe keratoconjunctivitis sicca (dry eye).



CEQUA is formulated with nanomicelle technology\*

\*Clinical significance is unknown.

### Clinical use:

**Pediatrics (<18 years of age):** The safety and effectiveness of CEQUA has not been established in pediatric patients; therefore, Health Canada has not authorized an indication for pediatric use.

**Geriatrics (>65 years of age):** No overall differences in safety or effectiveness have been observed between elderly and younger adult patients.

### Contraindications:

- Patients who are hypersensitive to this drug or to any ingredient in the formulation or component of the container
- Patients with active or suspected ocular or peri-ocular infection
- Patients with ocular or peri-ocular malignancies or premalignant conditions

### Relevant warnings and precautions:

- For topical ophthalmic use only

**REFERENCE:** Current CEQUA™ Product Monograph, Sun Pharma Global FZE.

- Resolve existing or suspected ocular or peri-ocular infections before initiating CEQUA treatment. If an infection occurs during treatment, CEQUA should be temporarily withheld until the infection has been resolved
- Patients should be advised not to drive or use machines until their vision has cleared after CEQUA administration
- CEQUA has not been studied in patients with a history of *herpes keratitis*, end stage lacrimal gland disease, keratoconjunctivitis sicca (KCS) secondary to the destruction of conjunctival goblet cells such as occurs with Vitamin A deficiency, or scarring, such as occurs with cicatricial pemphigoid, alkali burns, Stevens-Johnson syndrome, trachoma, or irradiation
- Patients with severe keratitis should be carefully monitored
- Potential for eye injury and contamination
- CEQUA should not be administered while wearing contact lenses

- Local infections and malignancies: Regular monitoring of the eye(s) is recommended when CEQUA is used long term
- Hypersensitivity reactions
- The effect of CEQUA has not been studied in patients with renal or hepatic impairment
- CEQUA is not recommended during pregnancy unless the benefits outweigh the risks
- Caution should be exercised when CEQUA is administered in nursing women

### For more information:

Please consult the Product Monograph at [https://pdf.hres.ca/dpd\\_pm/00060038.PDF](https://pdf.hres.ca/dpd_pm/00060038.PDF) for important information relating to adverse reactions, interactions and dosing information, which have not been discussed in this piece. The Product Monograph is also available by calling our medical department at 1-866-840-1340.

# ABOUT THE AUTHORS



**DAVID RP ALMEIDA, MD, MBA, PhD:** David RP Almeida is a Board-Certified Ophthalmologist and Vitreoretinal Surgeon. He completed an Honors Bachelor of Science (University of Toronto, Canada), PhD in Pharmaceutical Drug Research (University of Szeged, Hungary), MBA in healthcare management (The George Washington University, USA), medical school (Queen's University, Canada), ophthalmology residency (Queen's University, Canada) and a vitreoretinal disease and surgery fellowship (University of Iowa, USA). Dr. Almeida is part of Erie Retinal Surgery, a retina-only practice in Pennsylvania, and is the Director of Clinical Research at Erie Retina Research. He has over 200 peer-reviewed publications and over 150 national and international conference and keynote presentations, demonstrating a longstanding commitment to research.



**ERIC K. CHIN, M.D:** Eric K. Chin is a Board Certified ophthalmologist and a native of Northern California. He graduated from the University of California Berkeley with a bachelor's degree in Bioengineering. He received his medical degree from the Chicago Medical School. He completed his ophthalmology residency at the University of California Davis, and his surgical vitreoretinal fellowship at the University of Iowa. During his residency and fellowship, he was awarded several accolades for his teaching and research in imaging and novel treatments for various retinal diseases. Dr. Chin is trained in all aspects of vitreoretinal medicine and surgery, as well as uveitis and ocular tumors. He serves as Clinical Faculty at Loma Linda University and the Loma Linda Veterans Affairs Hospital where he teaches residents as well as gives lectures. He has numerous publications in major ophthalmic journals and textbooks. He is a member of many professional societies and a reviewer for several peer-reviewed ophthalmology journals.

# Trocar-based Surgical Technique for Drainage of Suprachoroidal Hemorrhages

David RP Almeida<sup>1</sup>, MD, MBA

Eric K. Chin<sup>2</sup>, MD

## Affiliations:

1. Erie Retinal Surgery & Erie Retina Research, Erie, Pennsylvania, USA
2. Retina Consultants of Southern California, Redlands, California, USA; Loma Linda University Medical Center; Veterans Affairs Hospital, Loma Linda, CA

## Correspondence:

David RP Almeida  
Email: drpa@pm.me

## Financial Disclosures:

None to report

## Introduction:

Suprachoroidal hemorrhage (SCH) most commonly occurs during or following intraocular surgery or in the setting of trauma. SCH requires early recognition and appropriate monitoring to prevent severe vision loss. Fortunately, some cases of SCH are self-limited and can resolve spontaneously with careful observation. However, in cases of large, progressive or appositional SCH, surgical drainage is often necessary to prevent further complications such as retinal detachment; angle-closure glaucoma; retinal incarceration; or expulsion of intraocular contents, all of which can be associated with permanent vision loss and a guarded prognosis.<sup>1-3</sup>

The traditional approach to SCH drainage involves external drainage via a 2.0 mm to 3.0 mm sclerotomy window or tunnel at the apex of the choroidal detachment. In some cases, a cyclodialysis spatula can be introduced into the suprachoroidal space to expedite outflow.<sup>1</sup> Problematically, this technique can often result in post-operative leakage and hypotony, endophthalmitis, retinal incarceration, and the need for subsequent pars plana vitrectomy (PPV). Although transconjunctival trocar-cannula drainage techniques have been previously described in the literature, there is often ambiguity and ambivalence regarding vitreous substitutes (e.g., air vs gas, vs silicone oil tamponade) following drainage of choroidal hemorrhage. Here, we

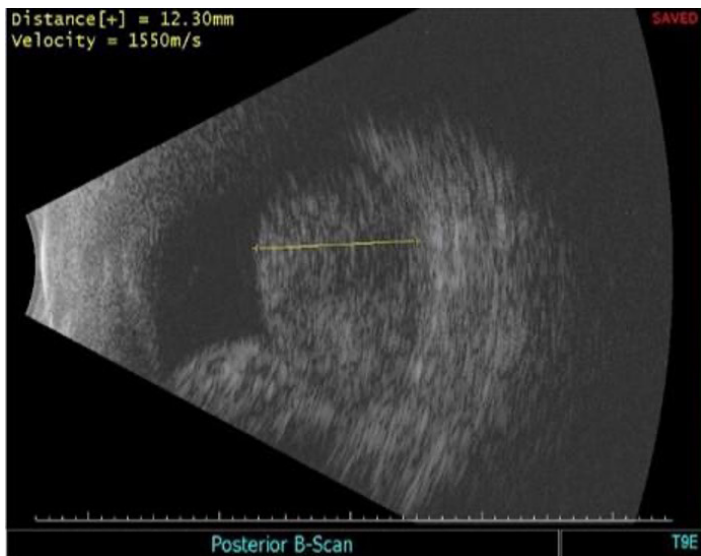
discuss and present a case demonstrating external trans-conjunctival drainage of SCH utilizing vitreoretinal trocar-cannulas on a patient with SCH following glaucoma surgery. Additionally, we discuss the efficacy and safety advantages of this surgical approach compared to those of previous drainage methods.

## Painful Loss of Vision Following Glaucoma Surgery

A 92-year-old female presented with painful vision loss in the left eye (OS) and was found to have appositional (“kissing”) SCH following trabeculectomy surgery for advanced glaucoma (**Figure 1**). Past ocular history included selective laser trabeculoplasty, trabeculectomy with mitomycin C and a Baerveldt glaucoma drainage device with scleral patch OS. Presenting best-corrected visual acuity (BCVA) was counting fingers at 3 feet with an intraocular pressure of 8 mmHg OS. Anterior segment examination demonstrated pseudophakia, a well-positioned Baerveldt tube and a 1 mm hyphema. The patient was monocular with hands motion vision OD secondary to advanced glaucoma. After discussing treatment options with the patient and her family, the decision for surgical drainage of the SCH OS was made given the patient’s monocular status and persistent ocular pain OS.

## Trocar-based Surgical Technique


Pre-operative B-scan echography was first performed to determine the ocular quadrant with the largest



**Figure 1.** B-scan echography performed before surgical intervention demonstrates a large suprachoroidal hemorrhage with retinal contact OS; image courtesy of David Almeida, MD

component of SCH. Ultrasound B-scan is a valuable tool in evaluating suprachoroidal hemorrhage (SCH). In cases where blood has liquified, the echogenicity of the hemorrhage decreases, appearing as a more hypoechoic region compared to the surrounding structures. This change in echogenicity can be attributed to the breakdown of the blood clot into smaller components and its subsequent liquefaction. Moreover, a liquified suprachoroidal hemorrhage often exhibits a more distinct, well-defined border with adjacent structures. This feature helps differentiate it from other causes of choroidal detachments or masses, which may have a more irregular or ill-defined border. The presence of fluid-fluid levels can be indicative of blood liquefaction in suprachoroidal hemorrhage. This phenomenon occurs when the red blood cells settle at the bottom, while the serum portion remains at the top, creating a layering effect within the hemorrhage. This layering can be identified on B-scan ultrasound as a distinct horizontal line separating the hypoechoic upper layer from the more echogenic lower layer. It is essential to consider these ultrasound characteristics when evaluating suprachoroidal hemorrhages to determine if the blood has liquified, as this information can impact management decisions and provide prognostic information.

The quadrant with an SCH height greater than 5 mm for optimal drainage was selected. Subsequently, an anterior infusion was secured at the corneal limbus using a 25-gauge trocar-cannula, and the IOP was temporarily elevated to 60 mmHg. With the IOP elevated to 60 mmHg, a 23-gauge, non-valved trocar-cannula was inserted approximately 7 mm posterior from the corneal limbus (i.e., roughly near



**Figure 2.** Schematic illustration demonstrating insertion of a vitreoretinal trocar-cannula at a flat angle of incidence (approximately 20 degrees) to the sclera and positioned towards the functional equator; image courtesy of David Almeida, MD

the functional equator) in the previously identified quadrant with the largest SCH component. It is critical to technique success that the trocar-cannula is inserted parallel to the functional equator, and nearly flat or parallel to the conjunctiva and sclera with an angle of incidence of approximately 15-20 degrees. The trocar-cannula should be positioned toward the functional equator to ensure proper positioning for drainage (**Figure 2**).

Next, drainage of the SCH can proceed with minimal manipulation employing the non-valved 23-gauge cannula. Once the SCH is drained, the 23-gauge cannula can be removed; we recommend leaving the drainage site open without suture closure. When required, PPV can be performed in eyes with concomitant pathology. In the case described above, the patient improved to a visual acuity of 20/200 with stable IOP OS.

### Surgical Pearls

The technique described here provides an efficient, efficacious and reproducible surgical approach to managing SCH. Note that smaller 25-gauge non-valved trocars can be used for drainage; however, blood drainage may be slower and more likely to occlude with small blood clots. The sutureless approach uses beveled incisions to allow for slow passive effusion and adequate drainage of the choroidal hemorrhage, minimizing the likelihood of the post-operative hypotony sometimes seen in external drainage via larger sclerotomy wounds.

Several surgical pearls should be noted, including avoiding drainage at the 3- and 9-o'clock meridians to spare possible iatrogenic trauma to the ciliary nerve. Moreover, if possible, it is advised to drain the inferotemporal quadrant, as this will facilitate surgical access and be gravity-dependent for optimal blood evacuation. Finally, if concomitant PPV is required, limbal-based vitrectomy is preferred to avoid instruments inadvertently entering the suprachoroidal space.

When PPV is performed following SCH drainage, if endotamponade is desired, we recommend avoiding air as choroidal formation and possible SCH often recur during this step. A non-compressible medium such as balanced salt solution or silicone oil will prevent choroidal formation from pushing fluid posteriorly, thereby protecting the macula. Given the possibility of recurrent SCH, a non-compressible medium such as silicone oil or fluid offers the optimal mechanical approach to mitigating this risk.

## **Conclusion**

Trocar-based vitreoretinal drainage is a viable surgical technique to treat some types of suprachoroidal hemorrhage. Our case provides an overview of the surgical management of SCH utilizing external vitreoretinal trocar-cannula-based drainage. This safe and reproducible technique affords vitreoretinal surgeons improved maneuverability when encountering these uncommon but challenging cases of SCH.

## **References**


1. *Rezende FA, Kicking MC, Li G, Prado RF, Regis LG. Transconjunctival drainage of serous and hemorrhagic choroidal detachment. Retina. 2012 Feb 1;32(2):242-9.*
2. *Tarantola RM, Folk JC, Shah SS, Boldt HC, Abramoff MD, Russell SR, Mahajan VB. Intraoperative choroidal detachment during 23-gauge vitrectomy. Retina. 2011 May 1;31(5):893-901.*
3. *Ali BYFS, Kurup SK, Garg SJ. Dealing with hemorrhagic choroidal detachments. Retina Today. 2018:21-24.*

# Looking for more?

This journal is presented by Catalytic Health, publishers of open access scientific specialty journals. All articles appearing in this issue, as in all Catalytic Health journals, are available at no cost, and may be read and downloaded in their entirety from the journal's website.

Each of Catalytic Health's peer-reviewed specialty journals was developed as a practical resource for Canadian practitioners, providing useful perspectives on the latest innovations in care and real-world insights on current clinical approaches to disease management in Canada.

To learn more about Catalytic Health's scientific journals or to subscribe, please visit [catalytichealth.com/subscribe](http://catalytichealth.com/subscribe).



# ABOUT THE AUTHORS



**AMY BASILIOUS, MD:** Amy Basilio is a graduate from the Schulich School of Medicine & Dentistry, Western University. She is currently a retina research fellow at the Ivey Eye Institute and will be completing her Ophthalmology residency training at Western University.



**RAJEEV H. MUNI, MD:** Dr. Rajeev Muni is a staff vitreoretinal surgeon at St. Michael's Hospital, The Hospital for Sick Children and the Kensington Eye Institute in Toronto, Canada and is the Vice-Chair of Clinical Research in the Department of Ophthalmology and Vision Sciences, University of Toronto. Dr. Muni completed his medical degree at McMaster University, followed by a residency in ophthalmology and fellowship in vitreoretinal surgery at the University of Toronto. This was followed by a fellowship in pediatric vitreoretinal surgery at the University of Southern California and a Masters degree in clinical epidemiology from the Harvard School of Public Health. Dr. Muni leads an active clinical research program and has a keen interest in randomized clinical trials, particularly in vitreoretinal surgical conditions.



**VERENA R. JUNCAL, MD:** Verena R. Juncal, MD: Dr. Verena Juncal is currently a vitreoretinal surgeon at the Ivey Eye Institute and an Assistant Professor at the Department of Ophthalmology at Western University. She completed her Ophthalmology residency at the Federal University of Sao Paulo in Brazil. Following residency, she completed a surgical vitreoretinal fellowship training at St. Michael's Hospital, University of Toronto. Dr. Juncal is actively engaged in research and has published in various peer-reviewed journals and presented at numerous major retina conferences.

# Anti-VEGF Therapy in Pregnancy and Breastfeeding

Amy Basilious, MD<sup>1</sup>

Rajeev H. Muni, MD<sup>2</sup>

Verena R. Juncal, MD<sup>1</sup>

## Affiliations:

1. Department of Ophthalmology, Ivey Eye Institute, St. Joseph's Health Care, Western University, London, Ontario
2. Department of Ophthalmology and Vision Sciences, St. Michael's Hospital/Unity Health Toronto, Ontario

## Correspondence:

Dr. Verena Juncal

Email: verena.juncal@sjhc.london.on.ca

## Financial Disclosures:

Dr. Juncal and Dr. Basilious report no financial support or conflicts of interest.

Dr. Muni is a consultant to Alcon, AbbVie, Bayer, Bausch & Lomb, Novartis and Roche. Dr. Muni receives research funding and grants from Bayer, Novartis and Roche.

## Introduction

Anti-vascular endothelial growth factor (VEGF) is the mainstay of treatment for several visually debilitating diseases and is considered the standard of care for a number of conditions which may affect younger patients, including women of childbearing age. These commonly include, but are not restricted to, diabetic macular edema (DME), proliferative diabetic retinopathy (PDR) and myopic choroidal neovascularization (CNV). As in other areas of medicine, pregnant and breastfeeding women are often excluded from clinical trials due to the unknown side effect profile of new drugs. This lack of evidence regarding the safety of anti-VEGF agents in pregnancy and breastfeeding introduces challenges for clinicians seeking to counsel these patients, particularly because anti-VEGF injections may be often used for an extended period of time, depending on the nature of the retinal disease. As a precaution, anti-VEGF injections are generally not recommended for women who are either pregnant or breastfeeding, given that they are considered Category C drugs and there is limited data regarding their excretion in human breast milk.<sup>1,2</sup> Therefore, treatment of this group of patients is typically managed on a case-by-case basis, balancing the potential patient benefits with safety concerns for the infant.

Pregnancy can indeed exacerbate or induce retinal conditions that may require treatment with anti-VEGF drugs.<sup>3</sup> Each treatment decision must be individualized, taking into consideration the importance of the drug to the mother. In cases of PDR, laser photocoagulation can be safely performed. Focal laser photocoagulation may also be used to treat cases of non-center involving diabetic macular edema. As an alternative to anti-VEGF injections, intravitreal steroids can be used in cases of center-involving DME, macular edema secondary to retinal vein occlusions, or inflammatory conditions. However, the use of intravitreal steroids may also introduce their own risks of premature cataract formation and high intraocular pressure in this typically young patient population. Finally, other diseases, such as myopic CNV, currently have anti-VEGF injections as the mainstay of treatment.

There is evidence that anti-VEGF drugs reach the systemic circulation following an intravitreal anti-VEGF injection.<sup>4</sup> Once in the bloodstream, these medications become susceptible to reaching the breast milk - similar to other molecules, drugs and antibodies that are present in the mother's bloodstream and are known to cross into the breast



milk. The exact mechanism of how anti-VEGF drugs cross from the bloodstream into the breast milk remains unknown. Multiple variables likely play a role, including drug lipophilicity, molecular size and the drug level in the mother's blood.

Different anti-VEGF drugs have different systemic exposures amidst these molecules rapidly reaching the bloodstream after an intravitreal injection.<sup>4</sup> Among the anti-VEGF drugs that are most commonly used, bevacizumab, ranibizumab and aflibercept, systemic exposure following an injection has been shown to be highest with bevacizumab and lowest with ranibizumab.<sup>4</sup> In fact, following three monthly injections of each drug, there is no drug accumulation between the first and third doses of ranibizumab, as opposed to persistent accumulation observed with aflibercept and bevacizumab.<sup>4</sup> In addition, both intravitreal bevacizumab and aflibercept result in significant plasma VEGF suppression, with aflibercept demonstrating the greatest suppression levels.<sup>4</sup> In contrary, intravitreal ranibizumab results in mostly unchanged systemic VEGF levels.<sup>4</sup> Based on these results observed in the general population, it may be reasonable to assume that ranibizumab could be a safer option of intravitreal anti-VEGF drug to be used in the setting of pregnant and nursing patients.

### **Pregnancy**

It is known that VEGF is involved in the maintenance of fetal and placental vasculature during pregnancy, and that reduced VEGF levels can lead to defective embryogenesis and even fetal loss.<sup>5,6</sup> In addition, because of the effect of VEGF on blood pressure regulation, anti-VEGF drugs can potentially be associated with maternal pre-eclampsia.<sup>7</sup> Therefore, the use of anti-VEGF drugs during pregnancy is concerning due to the potential risks of maternal and fetal complications.

In a literature review compiling 20 cases of women who had been administered either bevacizumab or ranibizumab injections during pregnancy, the majority of reports showed cases of a single anti-VEGF injection used throughout various periods of gestation, including the first trimester, in which pregnancy continued uneventfully without any fetal or maternal complications.<sup>8</sup> Three miscarriages and one case of pre-eclampsia were reported. In all three cases of miscarriage, a single injection of bevacizumab had been administered up to five weeks of gestation; two miscarriages occurred within ten days following injection in women with no risk factors. Although it is challenging to determine a causative correlation

between an anti-VEGF injection and miscarriage, the short ten-day interval between both events raises a suspicion. The other case of miscarriage occurred two months post-injection in a mother with a high-risk age factor for pregnancy loss. Regarding the case that developed pre-eclampsia, this mother had additional cardiovascular risk factors and a causative effect was deemed to be less likely.

As a result of the lack of strong clinical evidence when it comes to the use of intravitreal anti-VEGF drugs in pregnant women, it is important to provide thorough patient counselling, explain the risks and benefits of this treatment, and discuss the existing findings in the literature. A personalized decision taking into consideration the risk of vision loss in the mother, along with the patient's gestational period and anticipated number of repeat injections, is recommended.

### **Breastfeeding**

VEGF-A is a molecule that is naturally present in high concentrations in the breast milk.<sup>9-12</sup> It is known to regulate local mammary gland development in the nursing mother, and it is an essential growth factor in infancy. VEGF-A plays an important role in the development of the infant's digestive system, as well as in neurogenesis, renal medullary microcirculation expansion, lung angiogenesis and alveolarization.<sup>12-16</sup> Infants receiving anti-VEGF injections for retinopathy of prematurity (ROP) have been found to have higher rates of neurodevelopmental impairment when compared to preterm infants undergoing laser treatment for the same.<sup>14</sup> This finding raises a concern that similar effects may be observed in infants who ingest breast milk containing anti-VEGF, in the event that anti-VEGF enters the infant's systemic circulation and causes suppression of VEGF-A systemically.

A small number of case reports have explored the issue of anti-VEGF excretion during breastfeeding. Initial reports of patients receiving intravitreal bevacizumab found no transfer of anti-VEGF into the breast milk, although a reduction of 35% in breast milk VEGF-A levels was observed two weeks following bevacizumab injection.<sup>17</sup> Conversely, a different clinical study that included nursing patients undergoing injections with ranibizumab and aflibercept demonstrated that both drugs were excreted into the breast milk.<sup>18</sup> Additionally, there was a corresponding reduction in VEGF-A levels in the breast milk. In this case series, a 37-year-old treatment-naïve woman with myopic CNV underwent injections with ranibizumab following 16 months of breastfeeding. She discontinued

breastfeeding and did not pump her breast milk outside of study visits. Ranibizumab was first detected on Day 3 post-injection, with levels increasing over time until Day 28. There was a decrease in VEGF-A levels in the breast milk on Day 1 onward. The second patient was a 37-year-old woman who continued to regularly breastfeed while receiving ranibizumab injections for myopic CNV. Interestingly, ranibizumab levels in her breast milk remained under the assay's detectable threshold. It was hypothesized that the conflicting findings between these two patients could have been related to the patient's respective breastfeeding status. In the patient who discontinued breastfeeding, the free drug that continued to reach the breast milk most likely continued to accumulate for several days, accounting for the increasing drug levels observed over time. Conversely, in the second patient, who continued to regularly breastfeed, all the samples showed drug levels below the assay's detectable threshold, most likely because the drug in the breast milk was constantly excreted and ingested by the infant, and never accumulated sufficiently to a point above the assay's threshold level. The third patient was a 24-year-old treatment-naïve woman who was administered aflibercept for DME and elected not to breastfeed. Breast milk could only be pumped on Days 1 through 4 post-injection, after which no further breast milk was produced. Aflibercept was first detected in the breast milk on Day 4 post-injection, and VEGF-A was found to be decreased from Day 1 onward.

In light of the small number of cases in the literature, it is challenging to draw definite conclusions regarding the clinical impact of anti-VEGF injections during breastfeeding. However, these reports have provided evidence that anti-VEGF agents can be excreted into the breast milk and can consequently reduce the local levels of VEGF-A. However, the potential impact of ingesting breast milk with reduced VEGF-A levels, that also contains anti-VEGF drug, remains unknown. Another important question is whether or not ingested anti-VEGF drugs are actually transferred into the bloodstream of the breastfed infant and whether, in turn, VEGF is found to be systemically suppressed in the infant.

Our most current clinical study focused on investigating these questions, as the key concern is the effect anti-VEGF drugs present in the breast milk might have on the infant. Our additional objective was to test a breastfeeding strategy that could potentially minimize the infant's exposure to anti-VEGF drugs present in the breast milk, which might allow mothers to safely receive injections. Our breastfeeding protocol involved

a three-day "pump and dump" strategy in which the nursing mother continuously pumped and discarded her breast milk for three days following an injection, then resumed breastfeeding her infant on demand after the third day. Preliminary results of this research suggest that this strategy appeared to minimize the infant's exposure to the drug: ranibizumab levels in the breastfeeding infant's serum remained undetectable and plasma VEGF-A levels remained similar to those encountered in control infants. Therefore, a three-day "pump and dump" strategy may be a feasible and possibly safe option for breastfeeding patients requiring anti-VEGF therapy.

### **Conclusion**

Performing a large-scale clinical study on this topic is extremely challenging, as this clinical scenario does not commonly present itself. However, every retinal specialist, and perhaps some comprehensive ophthalmologists, will most likely confront a similar scenario at one point during their career. With these small studies as the only evidence currently available in a setting of high clinical relevance of anti-VEGF therapy, their results may be extremely helpful in the discussion that physicians may have with this patient cohort.

## References

1. Lucentis™ (ranibizumab injection) Product Monograph. Novartis Pharmaceuticals Canada, 2015.
2. Eylea™ (aflibercept injection) Product Monograph. Bayer Inc., 2013.
3. Rosenthal JM, Johnson MW. Management of retinal diseases in pregnant patients. *Journal of Ophthalmic & Vision Research*. 2018 Jan;13(1):62.
4. Avery RL, Castellarin AA, Steinle NC, Dhoot DS, Pieramici DJ, See R, Couvillion S, Ma'an AN, Rabena MD, Le K, Maia M. Systemic pharmacokinetics following intravitreal injections of ranibizumab, bevacizumab or aflibercept in patients with neovascular AMD. *British Journal of Ophthalmology*. 2014 Dec 1;98(12):1636-41.
5. Ferrara N. Role of vascular endothelial growth factor in regulation of physiological angiogenesis. *American Journal of Physiology-Cell Physiology*. 2001 Jun 1;280(6):C1358-66.
6. Galazios G, Papazoglou D, Tsikouras P, Kolios G. Vascular endothelial growth factor gene polymorphisms and pregnancy. *The Journal of Maternal-Fetal & Neonatal Medicine*. 2009 Jan 1;22(5):371-8.
7. Granger JP. Vascular endothelial growth factor inhibitors and hypertension: a central role for the kidney and endothelial factors? *Hypertension*. 2009 Sep 1;54(3):465-7.
8. Polizzi S, Mahajan VB. Intravitreal anti-VEGF injections in pregnancy: case series and review of literature. *Journal of Ocular Pharmacology and Therapeutics*. 2015 Dec 1;31(10):605-10.
9. Siafakas CG, Anatolitou F, Fusunyan RD, Walker WA, Sanderson IR. Vascular endothelial growth factor (VEGF) is present in human breast milk and its receptor is present on intestinal epithelial cells. *Pediatric Research*. 1999 May;45(5):652-7.
10. Vuorela P, Andersson S, Carpén O, Ylikorkala O, Halmesmäki E. Unbound vascular endothelial growth factor and its receptors in breast, human milk, and newborn intestine. *The American Journal of Clinical Nutrition*. 2000 Nov 1;72(5):1196-201.
11. Nishimura S, Maeno N, Matsuo K, Nakajima T, Kitajima I, Saito H, Maruyama I. Human lactiferous mammary gland cells produce vascular endothelial growth factor (VEGF) and express the VEGF receptors, Flt-1 AND KDR/Flk-1. *Cytokine*. 2002 May 1;18(4):191-8.
12. Ozgurtas T, Aydin I, Turan O, Koc E, Hirfanoglu IM, Acikel CH, Akyol M, Serdar M, Erbil KM. Soluble vascular endothelial growth factor receptor 1 in human breast milk. *Hormone Research in Paediatrics*. 2011;76(1):17-21.
13. Nishimura S, Maeno N, Matsuo K, Nakajima T, Kitajima I, Saito H, Maruyama I. Human lactiferous mammary gland cells produce vascular endothelial growth factor (VEGF) and express the VEGF receptors, Flt-1 AND KDR/Flk-1. *Cytokine*. 2002 May 1;18(4):191-8.
14. Morin J, Luu TM, Superstein R, Ospina LH, Lefebvre F, Simard MN, Shah V, Shah PS, Kelly EN, Canadian Neonatal Network, Canadian Neonatal Follow-Up Network Investigators. Neurodevelopmental outcomes following bevacizumab injections for retinopathy of prematurity. *Pediatrics*. 2016 Apr 1;137(4).
15. Tinning AR, Jensen BL, Johnsen I, Chen D, Coffman TM, Madsen K. Vascular endothelial growth factor signaling is necessary for expansion of medullary microvessels during postnatal kidney development. *American Journal of Physiology-Renal Physiology*. 2016 Sep 1;311(3):F586-99.
16. Thébaud B, Abman SH. Bronchopulmonary dysplasia: Where have all the vessels gone? Roles of angiogenic growth factors in chronic lung disease. *Am J Respir Crit Care Med*. 2007; 175(10):978–985.
17. McFarland TJ, Rhoads AD, Hartzell M, Emerson GG, Bhavsar AR, Stout JT. Bevacizumab levels in breast milk after long-term intravitreal injections. *Retina*. 2015 Aug 1;35(8):1670-3.
18. Juncal VR, Paracha Q, Bamakrid M, Francisconi CL, Farah J, Kherani A, Muni RH. Ranibizumab and aflibercept levels in breast milk after intravitreal injection. *Ophthalmology*. 2020 Feb 1;127(2):278-80.

We're embracing new partnerships in retinal care

*to let life in*



© 2023, Bayer Inc.  
© TM see [www.bayer.ca/tm-mc](http://www.bayer.ca/tm-mc)  
PP-PF-OPHT-CA-0004-1  
EY359E

Your partner in ophthalmology.

# ABOUT THE AUTHORS



**GURKARAN S. SAROHIA, MD:** Dr. Sarohia completed his MD degree at the University of British Columbia and is currently an ophthalmology resident at the University of Alberta. He has published numerous peer-reviewed articles and presented his vision science research at international conferences. Besides his research endeavours, Dr. Sarohia is interested in global health and medical education.



**MATHEW M. PALAKKAMANIL, MD, MPH, FRCSC:** Dr. Palakkamanil completed his MD degree at the University of Calgary followed by a five-year ophthalmology residency at the University of Alberta. Concurrent to this residency training, he completed a Master of Public Health (MPH) with a focus on epidemiology at Harvard University. He then completed a glaucoma fellowship at Dalhousie University in Halifax, Nova Scotia. Dr. Palakkamanil is currently appointed as a Clinical Assistant Professor at the University of Alberta. He is actively involved in the training of medical students, residents, and fellows.

# Medical Management of Glaucoma for the Pregnant and Breastfeeding Patient

Gurkaran S. Sarohia, MD<sup>1</sup>;

Mathew M. Palakkamanil, MD, MPH, FRCSC<sup>1</sup>

## Affiliations:

1. Department of Ophthalmology and Visual Sciences, University of Alberta, Edmonton, AB

## Correspondence:

Mathew Palakkamanil, MD, MPH, FRCSC

Email: mpalakka@ualberta.ca

## Financial Disclosures:

M.P.: Honorarium: Bausch & Lomb

G.S.: none

## Background

Glaucoma is a progressive optic neuropathy which is relatively uncommon in childbearing age, with a reported prevalence of 0.16% between the ages of 18-40 years.<sup>1</sup> Glaucoma management among pregnant patients presents a challenging scenario to the treating physician. Even with its low prevalence in the United Kingdom, a country-wide survey has revealed that approximately 26% of ophthalmologists reported having treated a pregnant patient with glaucoma.<sup>2</sup> Perhaps due to this low prevalence, 31% of these ophthalmologists reported uncertainty about managing glaucoma in this population.<sup>2</sup> When treating pregnant or breastfeeding patients, one must consider the benefit of treatment for the mother while weighing this against the risks the treatment may pose for the mother and fetus/child. This highlights the importance of having a review which can serve as a reference for physicians when managing glaucoma in pregnant and/or breastfeeding patients.

## Glaucoma Progression and Pregnancy

Intraocular pressure (IOP) is the only modifiable risk factor in patients with glaucoma. In pregnancy, the aqueous humor formation rate stays constant, whereas the outflow facility increases, resulting in a decrease in IOP.<sup>3</sup> Accordingly, IOP declines at 18 weeks gestation; it decreases dramatically during the third trimester and early post-partum period, prior to rising back to normal levels as early as 6 weeks post-partum.<sup>4,5</sup> Furthermore, the central corneal thickness (CCT) is found to increase during the second and third trimester of pregnancy. The

increased CCT can potentially elicit falsely high IOP measurements.<sup>6</sup> Nonetheless, IOP fluctuations are unpredictable in patients with glaucoma and in those at high risk for developing glaucoma (e.g., family history of juvenile open-angle glaucoma). In light of this, approximately 10% of glaucoma patients experience IOP elevation and disease progression during pregnancy. Therefore, it is important that these patients be followed on a regular basis to capture any potential IOP elevation or visual field progression.<sup>7,8</sup>

## FDA Classification and Teratogenicity of Glaucoma Medications

Clinicians managing glaucoma in pregnancy must balance the risk of disease progression and the potential harm to the fetus or newborn. The Food and Drug Administration (FDA) has two labelling systems to aid clinicians in decision-making. Drugs that were approved prior to June 30, 2001 have been classified according to a five-letter system: Category A (deemed safe); Category B (possibly safe for use in pregnancy); Category C (adverse effects reported in animal studies); Category D (definite risks but possible benefits); and Category X (drugs with known risks to the fetus that cannot be outweighed by possible benefits).<sup>4,9</sup> This system, however, was overly simplistic, and had the potential for misinterpretation as a grading system. Therefore, the FDA has introduced a new labelling system for drugs approved as of June 30, 2001 which includes potential risks and risk summaries for pregnancy and lactation, as well as pregnancy exposure registries.<sup>4</sup>

## Medical Management of Glaucoma During Pregnancy

### Beta-blockers

#### *Systemic*

Beta-blockers are FDA Category C drugs that work by decreasing aqueous humor production through inhibition of cyclic adenosine monophosphate (cAMP) in the ciliary epithelium. Systemically, beta-blockers are the most used class of medication to treat cardiac conditions in pregnant women; however, data supporting their safety is limited.<sup>10</sup> The most recent review on systemic beta-blockers was conducted in 1988 by Frishman and Chesner who recommended that systemic beta-blockers be 1) avoided during the first trimester; 2) used at the lowest possible dose during pregnancy; and 3) discontinued two to three days prior to delivery to limit the effects on uterine contractility and to avoid possible neonatal complications.<sup>11</sup> Since then, a large case control study by Bergman et al demonstrated that beta-blockers were not associated with a higher risk of specific congenital anomalies.<sup>12</sup> However, Peterson et al did show an association of beta-blockers with small gestational age in infants, preterm birth and perinatal mortality.<sup>13</sup>

#### *Topical*

Ho et al conducted a large population-based study on ophthalmic preparations in which 77.5% of women were prescribed topical beta-blockers and found that there was no significant difference in the risk of low-birth-weight infants between mothers prescribed beta-blockers and the comparison cohort.<sup>14</sup> Moreover, Pellegrino et al followed pregnant females through a series of telephone interviews and did not find any negative impact of beta-blockers on pregnancy/fetal or neonatal outcomes.<sup>15</sup> Conversely, a smaller study of six females using topical beta-blocker therapy showed an increased risk of low-birth-weight infants.<sup>16</sup> Furthermore, Wagenvoort et al described a case of a pregnant female with 21-week gestation with a fetal cardiac arrhythmia.<sup>17</sup>

In the survey of British ophthalmologists cited above, 45% stated that they would utilize topical beta-blockers as first-line therapy,<sup>2</sup> most likely because systemic beta-blockers are frequently used during pregnancy. After reviewing the literature on both systemic and topical preparations, beta-blockers appear to be a relatively safe category of drugs when accompanied by frequent monitoring and

co-management with maternal fetal medicine and obstetric colleagues in consideration of the risk of fetal arrhythmia and uterine contractility.

### Prostaglandin analogues

#### *Systemic*

Prostaglandin analogues are FDA Category C drugs that increase uveoscleral outflow and are often first-line therapy for the majority of glaucoma patients. In the context of pregnancy, oral prostaglandins have been used to stimulate uterine contractions and terminate pregnancy.<sup>18</sup> Regarding potential risks during pregnancy, prenatal exposure to misoprostol, an oral prostaglandin analogue, has also been associated with increased risk of Mobius sequence and terminal transverse limb defects.<sup>19</sup>

#### *Topical*

Santis et al conducted a small observational study on ophthalmic preparations exploring the effects of latanoprost in eleven pregnant women. The study found no evidence of adverse effects of latanoprost on pregnancy or neonatal outcomes.<sup>20</sup> Overall, excluding the third trimester given the possible stimulation of uterine contractions, topical prostaglandin analogues appear to be safe during pregnancy. However, close monitoring of patients is beneficial as there is a paucity of clinical data in this context.

### Carbonic anhydrase inhibitors

Carbonic anhydrase inhibitors (CAIs) are FDA Category C drugs that work by reducing the secretion of aqueous humor. They can be used in oral forms such as acetazolamide and methazolamide, as well as in topical forms such as dorzolamide and brinzolamide. There have been reported cases of teratoma in neonates, as well as renal tubular acidosis and electrolyte imbalance in a neonate born to a mother taking oral acetazolamide.<sup>21-23</sup> Conversely, a questionnaire-based study of 101 women showed no evidence of adverse effects from acetazolamide use during pregnancy.<sup>24</sup> Similar results were also noted in a case series of 12 pregnant women with idiopathic intracranial hypertension receiving oral acetazolamide.<sup>25</sup> Unfortunately, the literature does not contain any clinical studies investigating the use of topical CAIs during pregnancy. Nonetheless, we recommend avoiding oral CAIs during pregnancy due to their potentially high-risk profile. Furthermore, given the lack of clinical studies, if topical CAIs are required during pregnancy, we suggest punctal occlusion and co-management with maternal-fetal medicine experts.

### **Alpha adrenergic agonists**

Brimonidine, a commonly prescribed alpha agonist, lowers IOP by decreasing aqueous humor production.<sup>4</sup> Brimonidine is the only FDA Category B drug available for glaucoma management during pregnancy. Much like the other classes, no well-controlled human studies have been conducted to rule out teratogenic effects. Nonetheless, with close monitoring, this drug can be used safely in early pregnancy. It is important to note that the medication can cross the blood-brain barrier; it should be discontinued close to the time of delivery as it can cause CNS depression and apnea in infants.

### **Medical Management of Glaucoma During Breastfeeding**

#### **Beta-blockers**

Beta-blockers have been approved by the American Academy of Pediatrics (AAP) for use during nursing; however, there is inconsistent evidence in the literature.<sup>4,26</sup> Two clinical studies found beta-blockers in breast milk to be at multi-fold concentrations compared to serum levels in nursing mothers using topical beta-blockers.<sup>27,28</sup> On the other hand, a case report by Madadi et al showed that the concentration of timolol was low, and unlikely to cause systemic toxicity to a newborn.<sup>29</sup> Given the conflicting evidence, children of breastfed mothers should be monitored for signs of beta blockade, and extreme caution should be employed in infants with cardiopulmonary disease.

#### **Prostaglandin analogues**

There is a paucity of evidence in the literature regarding the use of prostaglandin analogues during breastfeeding. Very low levels are present in breast milk, which are not expected to cause any significant adverse effects in breastfed infants.<sup>7</sup> The half-life of these eye drops is only approximately seventeen minutes; therefore, close care should be taken to avoid breastfeeding following eye drop administration, which should reduce any risks toward the infant.<sup>4</sup>

#### **Carbonic anhydrase inhibitors (CAIs)**

Oral and topical CAIs have been approved by the AAP for use during nursing.<sup>4,26</sup> There is limited data on the effects of CAIs in breastfeeding. A case report has shown that acetazolamide does transfer to the infant through breast milk; however, it concluded that in low doses it is unlikely to cause any harmful effects.<sup>30</sup> The rare potential side effects to the infant include respiratory problems and impaired renal and hepatic function.<sup>4</sup> Therefore, both oral and topical carbonic anhydrase inhibitors are considered relatively safe during lactation when accompanied by adequate monitoring for side effects.

### **Alpha adrenergic agonists**

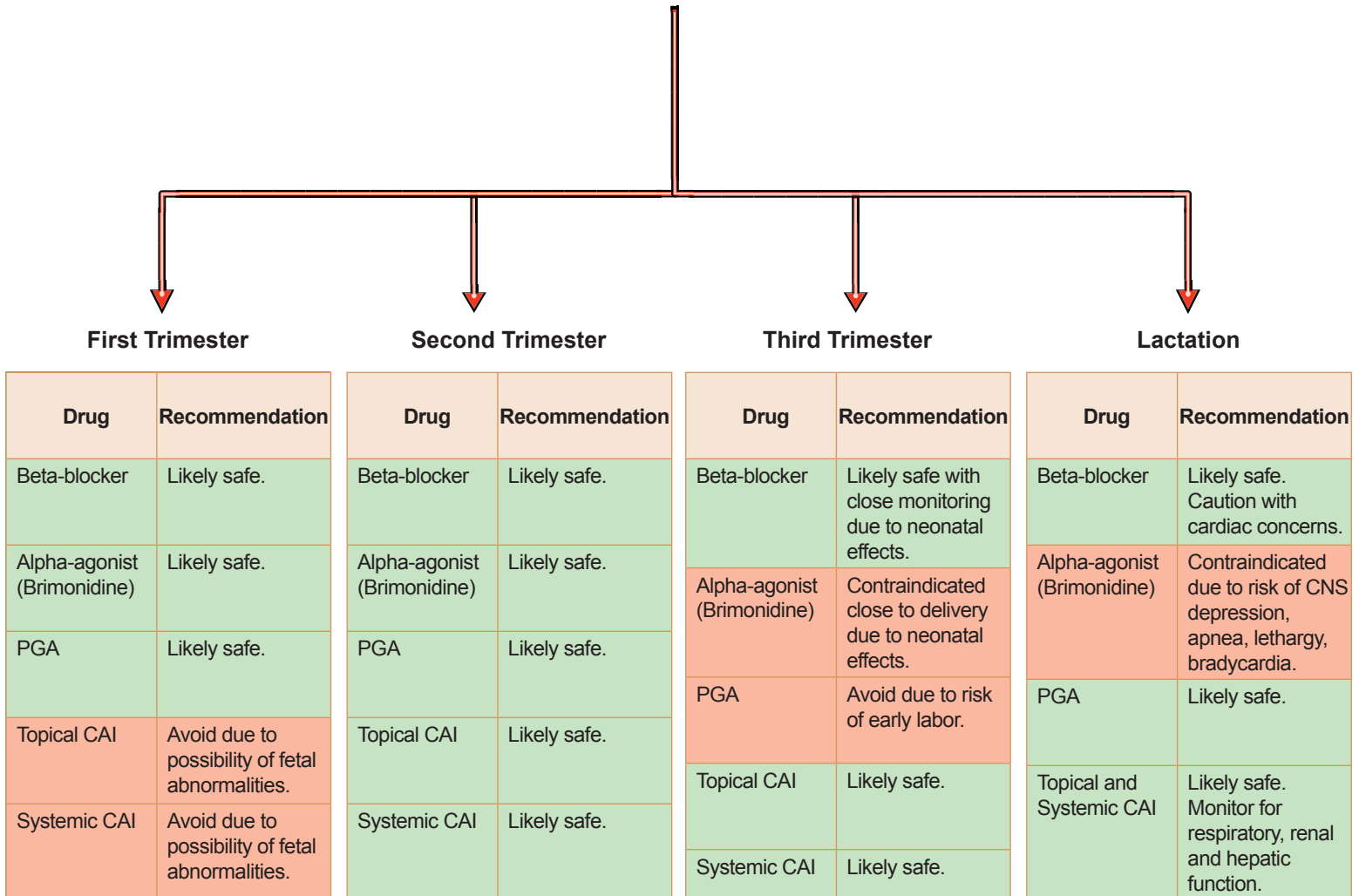
There is a paucity of data regarding the effects of brimonidine during breastfeeding. However, topical brimonidine is contraindicated in infants and small children due to the risk of CNS depression. Given that brimonidine is secreted in breast milk, it is absolutely contraindicated for use in nursing mothers.

### **Conclusion**

Glaucoma management during pregnancy and breastfeeding presents a challenge to both the treating ophthalmologist and the patient. Based on our review, there is a clear paucity of clinical studies on this topic. Decisions concerning the appropriate medication to use must be individualized for a patient and should consider the stage of pregnancy and severity of disease (**Figure 1**). Ideally, IOP should be optimized at the pre-conception stage with the use of laser, and surgical modalities, if necessary. If topical medications are required, effort must be taken to reduce systemic absorption with the use of punctal occlusion, eyelid closure and punctal plugs. Continued and regular communication between the treating ophthalmologist, obstetrician and pediatrician is paramount in developing a safe treatment plan that is mindful about prioritizing the health of the fetus/baby, along with vision preservation in the mother.



# Medical Management of Glaucoma in Pregnancy



**Figure 1.** An algorithm for the medical management of glaucoma in pregnancy and breastfeeding; courtesy of Gurkaran S. Sarohia, MD; Mathew M. Palakkamanil, MD, MPH, FRCSC

## References

1. Marx-Gross S, Laubert-Reh D, Schneider A, Höhn R, Mirshahi A, Münzel T, Wild PS, Beutel ME, Blettner M, Pfeiffer N. The prevalence of glaucoma in young people: Findings of the population-based Gutenberg Health Study. *Deutsches Ärzteblatt International*. 2017 Mar;114(12):204. <https://doi.org/10.3238/ARZTEBL.2017.0204>
2. Vaideanu D, Fraser S. Glaucoma management in pregnancy: a questionnaire survey. *Eye*. 2007 Mar;21(3):341-3. <https://doi.org/10.1038/SJ.EYE.6702193>
3. Mathew S, Harris A, Ridenour CM, Wiroszko BM, Burgett KM, Scripture MD, Siesky B. Management of glaucoma in pregnancy. *Journal of Glaucoma*. 2019 Oct 12;28(10):937-44. <https://doi.org/10.1097/IJG.0000000000001324>
4. Belkin A, Chen T, DeOliveria AR, Johnson SM, Ramulu PY, Buys YM. A practical guide to the pregnant and breastfeeding patient with glaucoma. *Ophthalmology Glaucoma*. 2020 Mar 1;3(2):79-89. <https://doi.org/10.1016/J.OGLA.2019.12.004>
5. Sunness JS. The pregnant woman's eye. *Survey of ophthalmology*. 1988 Jan 1;32(4):219-38. [https://doi.org/10.1016/0039-6257\(88\)90172-5](https://doi.org/10.1016/0039-6257(88)90172-5)
6. Efe YK, Ugurbas SC, Alpaya A, Ugurbas SH. The course of corneal and intraocular pressure changes during pregnancy. *Canadian Journal of Ophthalmology*. 2012 Apr 1;47(2):150-4. <https://doi.org/10.1016/J.CJJO.2012.01.004>
7. Kumari R, Saha BC, Onkar A, Ambasta A, Kumari A. Management of glaucoma in pregnancy—balancing safety with efficacy. *Therapeutic Advances in Ophthalmology*. 2021 Jun;13:25158414211022876. <https://doi.org/10.1177/25158414211022876>
8. Mendez-Hernandez C, Garcia-Feijoo J, Saenz-Frances F, Santos-Bueso E, Martinez-de-la-Casa JM, Megias AV, Fernández-Vidal AM, Garcia-Sanchez J. Topical intraocular pressure therapy effects on pregnancy. *Clinical Ophthalmology*. 2012 Oct 8;1629-32. <https://doi.org/10.2147/OPHT.S36712>
9. New FDA Pregnancy Categories Explained - Drugs.com. <https://www.drugs.com/pregnancy-categories.html>. Accessed November 12, 2022.
10. Duan L, Ng A, Chen W, Spencer HT, Nguyen J, Shen AY, Lee MS.  $\beta$ -blocker exposure in pregnancy and risk of fetal cardiac anomalies. *JAMA Internal Medicine*. 2017 Jun 1;177(6):885-7. <https://doi.org/10.1001/JAMAINTERNED.2017.0608>
11. Frishman WH, Chesner M. Beta-adrenergic blockers in pregnancy. *Am Heart J*. 1988; 115:147-152. [https://doi.org/10.1016/0002-8703\(88\)90530-3](https://doi.org/10.1016/0002-8703(88)90530-3)
12. Bergman JE, Lutke LR, Gans RO, Addor MC, Barisic I, Cavero-Carbonell C, Garne E, Gatt M, Klungsoyr K, Lelong N, Lynch C. Beta-blocker use in pregnancy and risk of specific congenital anomalies: a European case-malformed control study. *Drug Safety*. 2018 Apr;41:415-27. <https://doi.org/10.1007/S40264-017-0627-X>
13. Petersen KM, Jimenez-Solem E, Andersen JT, Petersen M, Brødbæk K, Køber L, Torp-Pedersen C, Poulsen HE.  $\beta$ -Blocker treatment during pregnancy and adverse pregnancy outcomes: a nationwide population-based cohort study. *BMJ Open*. 2012 Jan 1;2(4):e001185. <https://doi.org/10.1136/BMJOPEN-2012-001185>
14. Ho JD, Hu CC, Lin HC. Antiglaucoma medications during pregnancy and the risk of low birth weight: a population-based study. *British Journal of Ophthalmology*. 2009 Oct 1;93(10):1283-6. <https://doi.org/10.1136/BJO.2008.157123>
15. Pellegrino M, D'Oria L, De Luca C, Chiaradia G, Licameli A, Neri C, Nucci M, Visconti D, Caruso A, De Santis M. Glaucoma drug therapy in pregnancy: literature review and teratology information. service (TIS) case series. *Current Drug Safety*. 2018 Mar 1;13(1):3-11. <https://doi.org/10.2174/1574886312666171030125804>
16. Razeghinejad MR, Nowroozzadeh MH. Anti-glaucoma medication exposure in pregnancy: an observational study and literature review. *Clinical and Experimental Optometry*. 2010 Nov 1;93(6):458-65. <https://doi.org/10.1111/J.1444-0938.2010.00526.X>
17. Wagenvoort AM, Van Vugt JM, Sobotka M, Van Geijn HP. Topical timolol therapy in pregnancy: is it safe for the fetus? *Teratology*. 1998 Dec;58(6):258-62.
18. Lipitz S, Grisar D, Libshiz A, Rotstein Z, Schiff E, Lidor A, Achiron R. Intraamniotic prostaglandin F2 alpha for pregnancy termination in the second and early third trimesters of pregnancy. *The Journal of Reproductive Medicine*. 1997 Apr 1;42(4):235-8.
19. Dal Pizzol TD, Knop FP, Mengue SS. Prenatal exposure to misoprostol and congenital anomalies: systematic review and meta-analysis. *Reproductive Toxicology*. 2006 Nov 1;22(4):666-71. <https://doi.org/10.1016/J.REPROTOX.2006.03.015>
20. Marco De S AL, Brigida C. Latanoprost exposure in pregnancy. *Am J Ophthalmol*. 2004;138. <https://doi.org/10.1016/j.ajo.2004.03.002>
21. Ozawa H, Azuma E, Shindo K, Higashigawa M, Mukouhara R, Komada Y. Transient renal tubular acidosis in a neonate following transplacental acetazolamide. *European Journal of Pediatrics*. 2001 Apr 1;160(5):321. <https://doi.org/10.1007/PL00008441>
22. Merlob P, Litwin A, Mor N. Possible association between acetazolamide administration during pregnancy and metabolic disorders in the newborn. *European Journal of Obstetrics & Gynecology and Reproductive Biology*. 1990 Apr 1;35(1):85-8. [https://doi.org/10.1016/0028-2243\(90\)90146-R](https://doi.org/10.1016/0028-2243(90)90146-R)
23. Worsham GF, Beckman EN, Mitchell EH. Sacrococcygeal teratoma in a neonate: association with maternal use of acetazolamide. *JAMA*. 1978 Jul 21;240(3):251-2. <https://doi.org/10.1001/JAMA.1978.03290030069029>
24. Falardeau J, Lobb BM, Golden S, Maxfield SD, Tanne E. The use of acetazolamide during pregnancy in intracranial hypertension patients. *Journal of Neuro-Ophthalmology*. 2013 Mar 1;33(1):9-12. <https://doi.org/10.1097/WNO.0B013E3182594001>
25. Lee AG, Pless M, Falardeau J, Capozzoli T, Wall M, Kardon RH. The use of acetazolamide in idiopathic intracranial hypertension during pregnancy. *American Journal of Ophthalmology*. 2005 May 1;139(5):855-9. <https://doi.org/10.1016/J.AJO.2004.12.091>
26. American Academy of Pediatrics Committee on Drugs. Transfer of drugs and other chemicals into human milk. *Pediatrics*. 2001 Sep;108(3):776-89. <https://doi.org/10.1542/PEDS.108.3.776>
27. Morselli PL, Boutroy MJ, Bianchetti G, Zipfel A, Boutroy JL, Vert P. Placental transfer and perinatal pharmacokinetics of betaxolol. *European Journal of Clinical Pharmacology*. 1990 May;38:477-83. <https://doi.org/10.1007/BF02336687>
28. Lustgarten JS, Podos SM. Topical timolol and the nursing mother. *Archives of Ophthalmology*. 1983 Sep 1;101(9):1381-2. <https://doi.org/10.1001/ARCHOPHT.1983.01040020383008>
29. Madadi P, Koren G, Freeman DJ, Oertel R, Campbell RJ, Trope GE. Timolol concentrations in breast milk of a woman treated for glaucoma: calculation of neonatal exposure. *Journal of Glaucoma*. 2008 Jun 1;17(4):329-31. <https://doi.org/10.1097/IJG.0B013E31815C3A5B>
30. Söderman P, Hartvig P, Fagerlund C. Acetazolamide excretion into human breast milk. *British Journal of Clinical Pharmacology*. 1984 May;17(5):599.

# ABOUT THE AUTHOR



**MARIE-CLAUDE ROBERT, MD:** Marie-Claude Robert is a clinical associate professor at the Université de Montréal. She obtained her undergraduate and medical degree from the University of Ottawa. She completed her residency at the Université de Montréal and her fellowship training in Cornea at the Massachusetts Eye and Ear. She manages and performs complex surgeries of the ocular surface, cornea and anterior segment for adult and pediatric patients. She is director of research in ophthalmology at the Centre Hospitalier de l'Université de Montréal and at the Centre Hospitalier Universitaire Sainte-Justine. Her research focus includes severe inflammatory ocular surface diseases and the development of artificial corneas.

## The Evolving Role of Women in Ophthalmology: Can They Truly Lean In?

### Marie-Claude Robert, MD

#### Affiliations:

Department of Ophthalmology, Université de Montréal, Montreal, Quebec  
Department of Ophthalmology, Centre Hospitalier de l'Université de Montréal (CHUM), Montreal, Quebec  
Department of Ophthalmology, Centre Hospitalier Universitaire Sainte-Justine

#### Correspondence:

Marie-Claude Robert  
Email: marie-claude.robert.2@umontreal.ca

#### Financial Disclosures:

None

**Acknowledgment:** I would like to thank Dr. Yvonne Buys for the tremendous work she has done documenting gender disparity in Canadian ophthalmology for over a decade. Her work and that of her colleagues has been instrumental in the preparation of this article.

#### Background

I will soon be celebrating the 10-year anniversary of my graduation from medical residency. As an ambitious, high-achieving individual, I have striven to do my best, courageously (and sometimes obliviously) confronting the various challenges that I have encountered. Over the years, I built my “village of support” and I was convinced I could have it all.

In those 10 years, I have completed a two-year fellowship, had three children, taken on several

research endeavours/projects and have risen through my university's academic ranks. I have a rewarding but busy practice caring for wonderful patients of all ages. I have had the opportunity to build an amazing career in ophthalmology. I have been able to “lean in”.

Ten years ago, leaning in became a call to action for high-achieving women like me. At that time, Sheryl Sandberg, the Chief Operating Officer (COO) at Facebook published a book entitled “Lean In: Women, Work, and the Will to Lead”.<sup>1</sup> Women were

encouraged to be confident and assertive, seizing opportunities for career advancement, as represented by the image of a strong woman physically leaning in at the head of the table. While this is all wonderful and encouraging, the phrase “lean in” places the responsibility of gender equality on women. However, female success and career fulfillment are products of societal conventions and involve pillars relating to gender equality. Equality is the term to emphasize the need to address the context of women’s status in society and their intrinsic role in childbearing and childcare (in contrast to equity, which is defined as placing men and women on equal footing in the workplace).

In the past decade, have women in ophthalmology truly been able to lean in? Each individual should be able to define what leaning in means for them, their family and their career. With the reality of life’s complexities, each individual needs to find the work-life balance to suit their personality and ambitions. In my view, a female ophthalmologist is leaning in when she feels empowered and satisfied “by the wind in her sails and the direction of her ship”. In this sense, female ophthalmologists are likely to be leaning in. Various studies reveal that female ophthalmologists in Canada appear to be very satisfied with their career and their satisfaction level is equal to that of male ophthalmologists.<sup>2,3</sup> On the other hand, burnout and depression are more common among female physicians.<sup>4</sup> How can one explain such discrepancies?

### **Female Ophthalmologists: The Numbers**

In 2020, women represented 27% of all ophthalmologists in Canada. However, the proportion of women in practice varies dramatically between provinces, from 11% in Newfoundland and Labrador to 41% in Quebec.<sup>5</sup> With Quebec as a leader in female representation in ophthalmology, I am fortunate to have had several amazing female mentors with laser-sharp acuity who have played a key role in fostering women’s success in the ophthalmology sector. Unfortunately, Quebec ophthalmology is an anomaly. All the other Canadian provinces fall below the national average for female representation in our specialty. Furthermore, the proportion of female ophthalmologists in Canada significantly lags the numbers found among physicians in general, where women represent 43.7% of the workforce.<sup>5</sup> Ophthalmology programs have been shown to admit female residents in similar proportion to that of male residents who apply, suggesting that there is no gender bias

in the selection process.<sup>6</sup> This is surprising as ophthalmology is often considered a “lifestyle” surgical specialty, perhaps more conducive to achieving the much sought after work life balance. So, the question remains as to why female medical students are not applying in the first place and what barriers potentially remain in place.

I navigated toward ophthalmology thanks to great mentors. Do we have sufficient female mentors in ophthalmology? In a recent study, women represented 23% of ophthalmology leaders, including 31% of department heads and 27% of residency program directors.<sup>7</sup> There is a similar proportion of male and female ophthalmologists achieving the title of full professor or other academic appointments.<sup>3</sup> Therefore, women hold a near representative proportion of leadership roles in the Canadian ophthalmology landscape.

### **What challenges remain?**

#### *Income*

Several studies have shown that female ophthalmologists earn less than their male counterparts.<sup>5,8-12</sup> While the fee for service payments in Canada may suggest that this discrepancy is due to women working less, Canadian female ophthalmologists have been shown to work hours similar to those of their male counterparts.<sup>3</sup> Alternative explanations are that female physicians provide longer consultation time (either by choice or by patient expectation) or that female physicians’ practices are systematically biased toward lower paying services.<sup>2,3</sup> For example, women are provided approximately half of their male counterparts’ operating time and surgical volume, despite similar clinical activity.<sup>2,3</sup> For every cataract surgery, female ophthalmologists conduct a significantly higher number of clinic visits which are remunerated at a lower rate.<sup>13</sup> In addition, men are much more likely to be high-volume cataract surgeons.<sup>1,14</sup> This difference may begin in residency, with female residents being given significantly less surgical volume and opportunity than their male counterparts.<sup>15</sup>

Furthermore, proportionally more men (41%) than women (15%) pursue fellowship training in the highest paid subspecialties such as vitreoretinal surgery. Conversely, U.S. data shows that more women pursue fellowship training in lower paying subspecialties such as pediatric ophthalmology (12%) and neuro-ophthalmology (3%), compared

to men (5% and 0% respectively).<sup>11</sup> Things are not very different in my department: Five out of six neuro-ophthalmologists and four out of six pediatric ophthalmologists are female, while 9 out of 11 vitreoretinal surgeons are male. Unfortunately, the pay gap persists even after controlling for factors including part-time work, practice type and subspecialty.<sup>16</sup>

Finally, male physicians reach peak productivity between ages 45 and 59, while female physicians reach peak productivity at 55 to 59 years of age.<sup>6</sup> This delayed and shorter productivity period is likely due to the fact that, in general, female ophthalmologists assume a greater share of domestic and childcare responsibilities, and are not able to reach peak productivity before experiencing an empty nest.<sup>2</sup>

### **Childbearing and childcare**

The decision to have children is entirely personal, with many wonderful reasons for and against. As stated above, childrearing is likely to have an impact on a female ophthalmologist's income. In addition, children provide ample opportunity to dispose of that income and create a perpetual mental load, which is often borne by women. While children are absolutely worth it, these factors may impede women's ability to lean in to their careers.

#### *To be or not to be (a mom ophthalmologist)*

In 2014, 90% of male and 81% of female Canadian ophthalmologists had children.<sup>3</sup> This trend toward lower natality among female ophthalmologists has been reported in a number of studies.<sup>10,17,18</sup> In addition, women have their children later than their male counterparts. In Australia and New Zealand, female ophthalmologists have their first child at an average age of 35.<sup>10,17</sup> By delaying childrearing until after their training, female ophthalmologists have less time to plan their family, and place themselves at higher risk of infertility and pregnancy complications.<sup>18</sup> Indeed, the rate of pregnancy loss for female surgeons is twice that of the general population.<sup>18</sup> Conversely, male ophthalmologists often begin their families during training with little to no impact on their training program. Consequently, female ophthalmologists are less likely to have three or more children than male ophthalmologists.<sup>3</sup> The age ranges of surgical training and childbearing tend to overlap and there is a need to find more flexible and adaptive methods to allow women to succeed at both.

#### *The emotional (and laundry) load*

Female ophthalmologists are much more likely to be the primary caregivers of their children when compared to male ophthalmologists.<sup>2,3,17</sup> The spouses of female ophthalmologists in Canada are more frequently employed full-time and are more often physicians themselves. Conversely, the spouses of male ophthalmologists are more frequently employed part-time or are not employed.<sup>2,3</sup> This additional load translates to 51% of female ophthalmologists believing that childbearing slowed their career versus 15% among men.<sup>3</sup>

I believe that several hidden challenges remain, which are often not discussed publicly. Society's perception of female physicians is different than that of male physicians in ways that cannot be accurately quantified. Patients expect a different level of empathy, communication and time from their female physicians. Taylor Swift explains this discrepancy beautifully: "There is a different vocabulary for men and women in the music industry. A man does something, it's strategic. A woman does the same thing, it's calculated. A man is allowed to react, a woman can only overreact." This inappropriate labelling exists in ophthalmology, as well. Female ophthalmologists receive a greater number of complaints than their male counterparts, especially in academic practices.<sup>19</sup> Female colleagues with long clinic wait times are labelled as "clueless," "not respectful" and "greedy" on the RateMD website. Male colleagues with similar wait times receive comments such as "excellent surgeon even if you have to wait" and "patients have to understand that this ophthalmologist has a subspecialty and his time is important". Similarly, significantly more female ophthalmology residents and fellows face workplace bullying or harassment.<sup>20,21</sup> Significantly more female physicians also report being humiliated, ignored, excluded, or unrecognized in the workplace.<sup>22</sup> Recognizing the bias in the hurtful comments mentioned above can only help empower young female physicians and change mindsets.

#### **Tips on Leaning In**

Confidence is a necessary tool for leaning in. Recognition and acknowledgment of gender biases have helped me understand the medical system, relieved me of some self-doubt, and provided me the poise and strength necessary for me to advocate for myself. Open communication with colleagues and mentors is an invaluable source of shared experiences, support and wisdom.

Organization is important and having an organized family life is dependent on all its members. Spouses, grandparents, nannies, neighbours, and the children themselves can be involved to allow for personal space to reflect on and engage in one's career. Shared calendars and chat groups are an excellent way to keep everyone in tune. Relationship and family goals, as well as task and mental load distribution, should be discussed early and continuously with one's partner.

In the end, leaning in is possible. We need to take ownership of our successes and merits. We need to acknowledge the gender imbalances that prevent the equal empowerment of our female colleagues. In the meantime, let's continue to put in the work to strive and thrive!

### References

- Sandberg S. *Lean In: Women, work and the will to lead*. New York: Knopf; 2013.
- Jinapriya D, Cockerill R, Trope GE. Career satisfaction and surgical practice patterns among female ophthalmologists. *Canadian Journal of Ophthalmology*. 2003 Aug 1;38(5):373-8.
- McAlister C, Jin YP, Braga-Mele R, DesMarchais BF, Buys YM. Comparison of lifestyle and practice patterns between male and female Canadian ophthalmologists. *Canadian Journal of Ophthalmology*. 2014 Jun 1;49(3):287-90.
- Wong AM. Beyond burnout: looking deeply into physician distress. *Canadian Journal of Ophthalmology*. 2020 Jun 1;55(3):7-16.
- Buys YM, Bellan L. Updated inventory and projections for Canada's ophthalmology workforce. *Canadian Journal of Ophthalmology*. 2022 Jul 1.
- Buys YM. Aging and feminization of the physician workforce in Canada: comparing ophthalmologists to all other physicians. *Canadian Journal of Ophthalmology*. 2014 Jun 1;49(3):291-6.
- Nguyen A, Wen Y, Tanya S, Hardy I. Analyse genrée du leadership et de l'impact scientifique chez les leaders de l'ophtalmologie universitaire canadienne. Université de Montréal Department of Ophthalmology Research Day; October 2022.
- Gill HK, Niederer RL, Shriver EM, Gordon LK, Coleman AL, Danesh-Meyer HV. An eye on gender equality: a review of the evolving role and representation of women in ophthalmology. *American Journal of Ophthalmology*. 2022 Apr 1;236:232-40.
- Reddy AK, Bounds GW, Bakri SJ, Gordon LK, Smith JR, Haller JA, Berrocal AM, Thorne JE. Differences in clinical activity and Medicare payments for female vs male ophthalmologists. *JAMA Ophthalmology*. 2017 Mar 1;135(3):205-13.
- Danesh-Meyer HV, Deva NC, Ku JY, Carroll SC, Tan YW, Gamble G. Differences in practice and personal profiles between male and female ophthalmologists. *Clinical & Experimental Ophthalmology*. 2007 May;35(4):318-23.
- Jia J, Lazzaro A, Lidder A, et al. Gender compensation gap for ophthalmologists in the first year of clinical practice. *Ophthalmology*. 2021;128:971-80.
- Buys YM, Canizares M, Felfeli T, Jin Y. Influence of age, sex, and generation on physician payments and clinical activity in Ontario, Canada: an age-period-cohort analysis. *American Journal of Ophthalmology*. 2019 Jan 1;197:23-35.
- Feng PW, Ahluwalia A, Adelman RA, Chow JH. Gender differences in surgical volume among cataract surgeons. *Ophthalmology*. 2021 May 1;128(5):795-6.
- Micieli JA, Trope GE, Buys YM. Gender gap and declining surgical activity among new graduates: cataract surgery in Ontario. *Canadian Journal of Ophthalmology*. 2016 Jun 1;51(3):154-60.
- Gong D, Winn BJ, Beal CJ, Blomquist PH, Chen RW, Culican SM, Glass LR, Domeracki GF, Goshe JM, Jones JK, Khouri AS. Gender differences in case volume among ophthalmology residents. *JAMA Ophthalmology*. 2019 Sep 1;137(9):1015-20.
- Grossman RC. *The Gender Pay Gap in Medicine: Causes and Solutions*. In: *Gender Equity in the Medical Profession 2020* (pp. 110-127). IGI Global.
- Jain NS, Kersten HM, Watson SL, Danesh-Meyer HV. Gender differences in Australasian ophthalmologists' experiences of the workplace. *Clinical & Experimental Ophthalmology*. 2019 Aug;47(6):706-12.
- Rangel EL, Castillo-Angeles M, Easter SR, Atkinson RB, Gosain A, Hu YY, Cooper Z, Dey T, Kim E. Incidence of infertility and pregnancy complications in US female surgeons. *JAMA Surgery*. 2021 Oct 1;156(10):905-15.
- Kohanim S, Sternberg Jr P, Karrass J, Cooper WO, Pichert JW. Unsolicited patient complaints in ophthalmology: an empirical analysis from a large national database. *Ophthalmology*. 2016 Feb 1;123(2):234-41.
- Jain NS, Gill HK, Kersten HM, Watson SL, Danesh-Meyer HV. Bullying and harassment in ophthalmology: a trainee survey. *The New Zealand Medical Journal (Online)*. 2020 Apr 3;133(1512):102-3.
- Meyer JA, Troutbeck R, Oliver GF, Gordon LK, Danesh-Meyer HV. Bullying, harassment and sexual discrimination among ophthalmologists in Australia and New Zealand. *Clinical & Experimental Ophthalmology*. 2021 Jan;49(1):15-24.
- Rouse LP, Gallagher-Garza S, Gebhard RE, Harrison SL, Wallace LS. Workplace bullying among family physicians: a gender focused study. *Journal of Women's Health*. 2016 Sep 1;25(9):882-8.

now  
in Canada

# world leader in preservative-free eye care

Théa Pharma Canada is a subsidiary of Théa, a global leader and pioneer in ophthalmics, serving over 75 countries.

We are committed to providing preservative-free eye care products to eye care professionals who treat the anterior segment and ocular surface conditions. Our goal is to deliver uncompromising care that allows all stakeholders to envision the future of ophthalmic treatment with eyes wide open.



[www.theapharma.ca](http://www.theapharma.ca)  
1-888-805-THEA (8432)

learn more  
about Théa Pharma



Volume 2, Issue 2

# CANADIAN EYE CARE TODAY

SHARE OUR WEBLINK ON YOUR  
SOCIAL MEDIA PLATFORM:



REGISTER FOR FUTURE DIGITAL AND PRINT ISSUES BY  
VISITING US AT [CANADIANEYECARETODAY.COM](http://CANADIANEYECARETODAY.COM)

CALLING ALL AUTHORS! DO YOU HAVE A TOPIC THAT  
YOU WOULD LIKE TO SEE COVERED IN 2023?

DROP US A LINE AND TELL US ABOUT IT  
OR SEND US A SHORT ABSTRACT

INTERESTED IN RECORDING A PODCAST?  
WE WANT TO EXPLORE TOPICS WITH YOU!

EMAIL US: [INFO@CATALYTICHEALTH.COM](mailto:INFO@CATALYTICHEALTH.COM)